



Evolution & Treatment of the E Foot Type

It's important to recognize and treat this as early as possible.

BY LOUIS J. DECARO, DPM

Understanding the E-Quad

To begin, understand that children's feet will eventually evolve into one of 24 adult foot types (Chart 1), which can be reduced to six major subgroups, called quads (letter coded A through F). A quad is a group of foot types all functioning similarly.¹ Once foot maturation occurs each foot type is easily identified by simply observing some simple postural and gait characteristics such as arch height, transverse plane forefoot position or "toe-sign", callus patterns, and angle of gait (in-toe versus out-toe, abductory twist, etc.). Additionally, because of the nature of each foot type and its distinctive gait patterning, each foot type will present with predictive pain syndrome chief complaints that will vary at different stages.

The E-Quad is one of the most important foot types impacting a child's foot development between the ages of 7-10, and it represents approximately 23% of adult feet. It is an interesting foot type because the rearfoot is restricted in subtalar joint pronation during contact phase (i.e., an uncompensated rearfoot varus), and it is coupled with a rigid forefoot varus as well. This results in a foot that has difficulty loading the medial column during stance phase of gait. The primary way the body compensates for this morphological state is by rapidly pronating the forefoot upon heel rise and commonly throughout propulsion. This excessive forefoot motion can cause

a torque or twisting motion (i.e., a medial heel whip or abductory twist) which can deleteriously affect the kinetic chain on so many levels. Because of this, it is important to identify how and when it begins to present itself in a child's foot developmental years using age-specific parameters.

metatarsal is structurally elevated off the ground more than the 3rd, 4th, and then 5th. The greater the met 2-5 difference, the greater the forefoot varus. As podiatrists, we recognize that in some cases, a forefoot varus can be rigid and sometimes it can be flexible. A flexible forefoot varus is an acquired posi-

The E-Quad is one of the most important foot types impacting a child's foot development between the ages of 7-10, and it represents approximately 23% of adult feet.

Let's review what makes up an E-Quad foot type. This foot type is on the left side/column of the chart. The left column represents the rearfoot varus foot types, or more simply "the foot types with arches." The arch height can vary greatly in this foot type but is most often medium to somewhat low as assessed by vertical arch height in standing. This is because vertical arch height is primarily dependent on rearfoot position. The E-Quad tends to have a larger, more uncompensated, rearfoot varus that limits subtalar joint pronation and results in heavy loading on the lateral heel upon initial impact in gait.

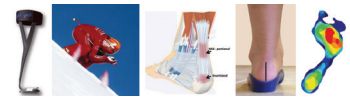
But what makes this foot so unique is that it also has forefoot varus. A varus implies that the 2nd

tional malalignment of the forefoot (forefoot "supinatus") that can be reducible and part of the pes planovalgus foot type (The F-Quad foot group). Alternatively, a rigid forefoot varus is a structural deformity created by an inverted frontal plane alignment of the talar head and neck that evolves during early childhood development (ages 7-10). Such is the case that occurs with the E-Quad, which is a combination of an uncompensated rearfoot varus and a rigid forefoot varus.

Land, Twist, Drop

Now that we know what makes up the E foot type, what does the adult foot (10 years old+) look like when the patient is standing in front

Continued on page 83



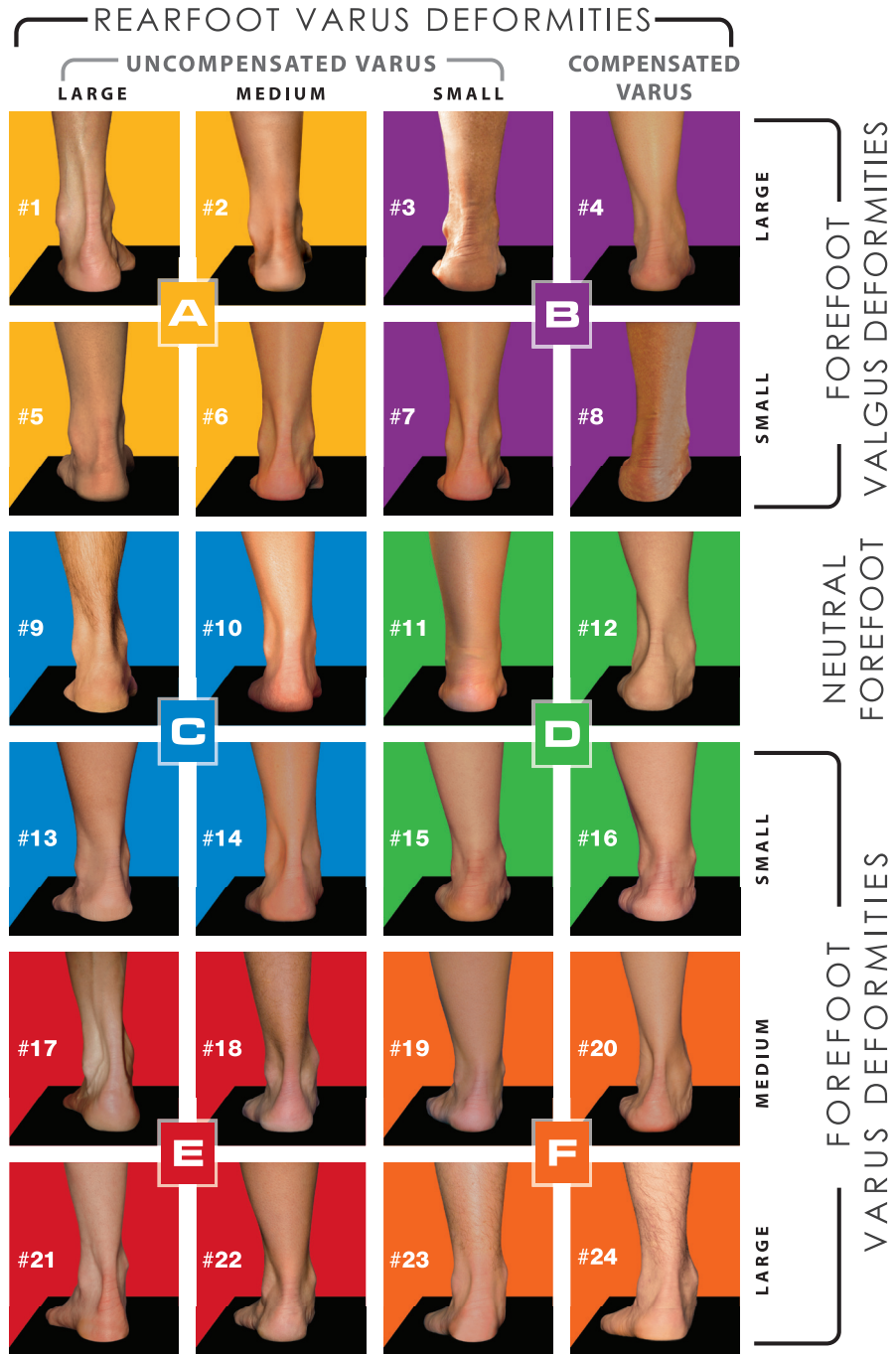
QUADRASTEP SYSTEM®

The QUADRASTEP SYSTEM® is based on a clinical algorithm* identifying 24 unique foot types. These 24 foot types are subdivided into 6 groupings of 4, known as "QUADS". Each QUAD has its own very specific foot and gait characteristics.

Why Treat all feet the same?

An individual's foot type (quad type) can influence not only how they walk, but the conditions and pathologies that may afflict them throughout their lives. Unlike other pre-fabricated orthoses that have a "one-size-fits-all" limitation, the QUADRASTEP SYSTEM® offers a more tailored solution for each foot type.

24 FOOT-TYPE ASSESSMENT MODEL



*U.S. Patent No. 7,789,840

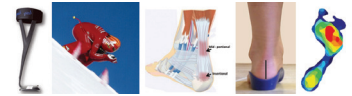
LEFT FEET SHOWN ABOVE

877.792.4669

n o l a r o 2 4 . c o m

a product of
NOLARO 24 LLC

Chart 1: Quadrastep System of Foot Typing



E Foot Type (from page 81)

of you? If you ask an E-Quad patient to stand in subtalar neutral, you will observe the heel and forefoot lift off the ground medially (uncompensated rearfoot varus combined with a forefoot varus). When standing in a relaxed position (RCSP), you will note pronation as evidenced by internal rotation of the tibia and medial ankle strain, with flattening just below the medial malleolus. The arch will displace through a combination of medial drift along with a drop in vertical height. Although the heel may “appear” to be in valgus, rest assured this is not possible because the rearfoot varus is uncompensated. The apparent heel valgus is caused by pronation of the ankle, pronation about the oblique axis of the midfoot, and lateral migration of the infracalcaneal fat pad. Pronation at the midfoot is the direct result of the rigid forefoot varus that causes heavy loading of the 5th metatarsal head at foot flat.

Since the forefoot is elevated from the ground medially, the foot will demonstrate a medial heel whip, also called an abductory twist, with resultant abduction of the forefoot that creates a positive toe sign. We refer to this as a “creasing toe sign” because there is a characteristic bend at the base of the 5th met that is caused by progressive midfoot breakdown leading to an odd “reverse-last-ed” foot shape, with the forefoot bending laterally instead of assuming a more typical adducted alignment. (Figure 1)

This foot type creates big problems in gait. Why? Because every step taken by an E-quad patient involves a lot of excessive rotational motion and forces that can lead to repetitive stress and strain on the shins (tibial stress syndromes, anterior and posterior tibial tendinitis), 5th Met calluses and tailor bunions, and growth plate problems in kids (Os-good Schlatter’s and Sever’s disease).

Patients should be told, “Every time you take a step, you are landing on the outer border of your foot, with

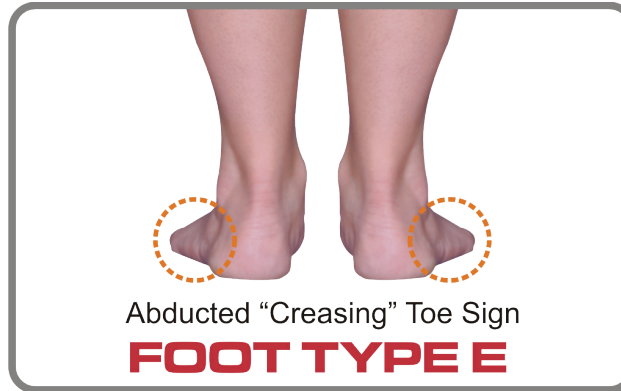

Figure 1: Creasing toe sign found in E-Quad foot.

the inside of your foot elevated from the ground. The only way you can get the big toe side of your foot on the ground is to twist and ultimately this

Early Stages

When does this all begin in life? During early childhood development, the talus and tarsal bones are undergoing torsional changes that ultimately cease around the ages 7-10, resulting in the acquisition of a child’s adult foot type. However, it is vitally important to understand that kinetic chain destruction occurs prior to adult maturation. In fact, it begins the minute we take our first steps.

It is important to understand that a child’s foot type begins to evolve from the time they begin walking, around 12-14 months. Val-massy’s well established “Rule of 7”

**It is important to understand that
a child’s foot type begins to evolve from the time
they begin walking, around 12-14 months.**

happens very quickly, and you land drop forcefully down onto the big toe at the end of the step. Then repeating each step: land, twist, drop—land twist drop—over and over again until ultimately something gives, and you develop pain and trauma.”

explains that between ages one to six, it is “normal” for a toddler’s feet to be pronated or “flat”. But by age seven, the heel should assume a vertical heel to floor alignment in standing and a more “normal” arch should appear.²

Continued on page 84

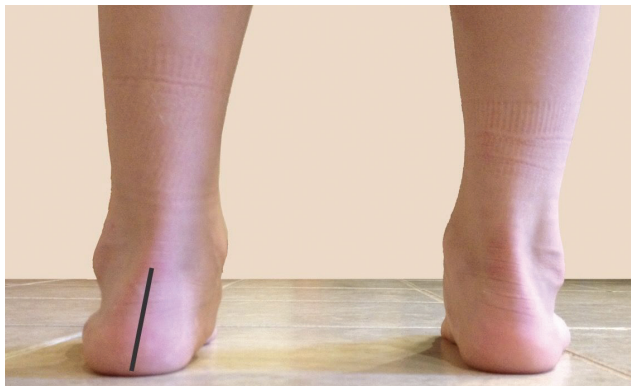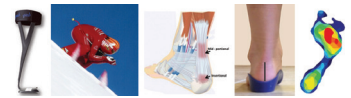


Figure 2a: 6 year old patient before orthotics.

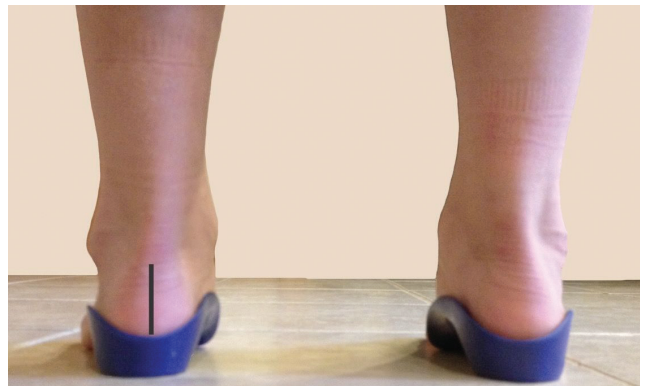


Figure 2b: 6 year old patient after orthotics.

E Foot Type (from page 83)

In the Quadrastep method of foot typing, it is believed that these torsional changes in foot structure will slow down a bit, but continue during the pre-teen years; and ultimately by age 10 the most ideal heel to floor position in resting calcaneal stance should be a 4-5 degrees inversion.

Even though we cannot truly diagnose an adult foot type until age 7-10, there are distinct attributes of an E-Quad foot type that have been noted in practice and through a study of genetics that can begin to reveal themselves at a very early age. Albeit you would not treat a prospective E quad (example, a one-year-old) the same way you would treat an adult E-Quad (Ages 7-10 and up), it is still worth noting and watching. Also be aware that treating a child as early as possible with foot orthotics won't necessarily change the morphology of the foot type, but it can help to avoid future problems that may otherwise be inevitable. Finally, it is extremely important to note that pain is not the only reason to treat. In fact, many of the symptoms of the E foot type under the age of seven can and will present without pain.

When evaluating a child prior to the age of seven, who we all know and accept will have at least a certain level of "normal" flat footedness, we find ourselves faced with the proverbial decision to make of 'to treat or not to treat' with orthotics. So, how then do we know what to do? I have been using and advising colleagues to use "The DeCaro Rating Scale" for when and why to treat pediatric flatfoot in

the under-seven population. The rating scale applies only to the flexible flat-foot, not a rigid flatfoot in which more significant measures may be required. The DeCaro rating scale is made up of several measures. Measures include, but are not limited to, the measured degree of flat footedness, family history of foot types (genetic disposition),

crease core/hip strength, improve endurance, and help prevent symptoms (painful and not) of the maturing E foot type.

7-10 Years

The next age cohort to examine is the 7-10 year-olds. As we said prior in the article, a foot can mature as

E quad children can begin to experience problems around these ages that might include heel or knee growth plate issues such as Sever's or Osgood-Schlatter's disease.

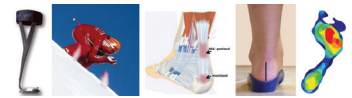
and how the foot may impair the child (clumsiness, weakness, endurance, or general gait impairment).

Toddlers presenting with an E-Quad foot, especially kids born with developmental delays, will suffer the most in core strength and hip strength deficits. They are often delayed ambulators, they may suffer from postural deficits, or have a "Weebly-wobbly" gait with lack of stability, and they may trip or fall or bump into walls. Some of these kids may be labeled as "lazy" since behaviorally they may avoid physically challenging activities. A stable foundation is critical in the development and strengthening of a child with an E-Quad foot structure as these children will face more physical challenges and be at higher risk of injury unless we intercede with orthotic support. Treating these children with a deep functional 30mm depth UCBL orthotic (OTC or custom) can and will improve their posture, help in-

crease core/hip strength, improve endurance, and help prevent symptoms (painful and not) of the maturing E foot type. The combination of the rearfoot and developing forefoot varus create a torque effect on the growth plate of the calcaneus and tibia, allowing this pain to occur.

The other major presenting 7-10 year old is a child who has some "growing pains" somewhere in their lower extremity chain. Physicians often report that "growing pains" ONLY occur in the lower part of the kinetic chain (hips down). Does the upper body not grow? The reason for growing pains is often obvious, however; it is the same torquing motion from the rearfoot and forefoot varus needing to pronate, which cre-

Continued on page 86



E Foot Type (from page 84)

ates the initiation of pain. These kids often cry to sleep at night, or have their parents rub their feet/legs every night, and/or need anti-inflammatories all too often, sometimes for years and years. Remember, however, “growing pains” can be seen even earlier in age than this.

When we think about treatment of these two age group categories (1-6 and 7-10), we typically treat the flexible flatfoot issues mainly with comprehensive rearfoot control. Imperative in successful orthotic treatment is a 30 mm depth heel cup with rearfoot posting, arch support combined with medial and lateral flanges in a functional device. (Figures 2a and 2b) However, sometimes, as early as seven years old, depending on the symptoms and foot type diagnosis, we may need to begin to post the forefoot, posting the forefoot extrinsically in any forefoot varus position 3 degrees and up. Often during this transitional time in foot maturity, if you are treating with just rearfoot control but the foot also requires forefoot control, the patient may tell you that the orthotic is uncomfortable in the arch or the navicular area is bothersome. At that point, forefoot posting may be warranted.

Teens and Adults

In the 11+ population, the E foot type presentation can add some more symptoms to the list. While Sever’s, Osgood-Schlatter’s, and growing pains can still persist, often kids involved in running sports will report a prevalence of shin splints, tibial stress fractures, and lower leg compartment syndrome. It is in fact the rapid abductory twisting of the E-Quad foot type which can cause tremendous torque forces on the lower leg, inducing these chief complaints. What is so remarkable is that often teenagers with one of these presenting symptoms will tell you that they also had growing pains as a “kid.” They will often communicate that they have been suffering from these issues for a while, and no one ever watched them walk! They also may tell you about many of the plethora of symptoms described here that




KEY ORTHOTIC FEATURES

- Medial RF & FF Posting
- 5th MTH Cut-Out
- 1st MTH Relief
- Mild Medial Flare

Great for Heel, Shin & Knee pain!

ABDUCTOVARUS FOREFOOT



Medial Heel Whip



- Narrow Heel Base Gait
- Restricted Subtalar Pronation
- Pivots at 5th MTH in Propulsion



MILD INTERNAL TIBIAL/FIBULAR ROTATION

MEDIUM-LOW ARCH



VARUS FOREFOOT ALIGNMENT



CALLUSES

FOOT PROGRESSION ANGLE

POSSIBLE CLINICAL SYMPTOMS

- Plantar Fasciitis / Heel Pain
- Shin Splints
- Knee Pain
- Tailor’s Bunionette
- Calcaneal Apophysitis (Sever’s Disease)
- Osgood-Schlatter Disease

Figure 3: Adult orthotic recommendations for the E-Quad foot type typically include a moderate heel cup depth with medial rearfoot posting, and extrinsic medial forefoot posting with a 5th Met cut-out.

can occur through childhood with the E-Quad foot type.

In the older adult population, we see knee pain, hip pain (hip abductor weakness, hip adductor tightening), IT band pain, and sometimes lower back pain. The aggressive pronation destructively climbs up the kinetic chain throughout adult life. Recurrent torque and strain (from the foot) on the leg and the muscles of the lower leg can cause all these various orthopedic pain syndromes. Adult orthotic recommendations for the E-Quad foot type typically include a moderate heel cup depth with medial rearfoot posting, and extrinsic medial forefoot posting with a 5th Met cut-out (Figure 3). Controlling this destructive motion properly and accurately is imperative.

In conclusion, the best way to treat the destructive nature of the E-Quad foot type is to treat it as early as possible. Recognizing the age-specific symptoms coupled with the genetics involved can be a powerful, life-altering treatment. It is prudent to understand foot types and related ankle and foot pathologies, because without some form of intervention, a patient is predisposed to certain pathological conditions of the foot

and/or ankle and up. Proper evaluation of foot type with subsequent prescribing of appropriate orthotics will go a long way in preventing many types of orthopedic issues.

Please remember to foot type ALL your patients, and “Prevention begets Correction!” **PM**

References

- ¹ Nole, Roberta: Foot-typing algorithm that identifies 24 variations of the normal human foot (US Patent 7,789,840).
- ² Valmassy, RL. Biomechanical evaluation of the child. Clin Podiatry, 1984; 1 (3):563-79.

Dr. DeCaro specializes in pediatrics with a special interest in sports medicine and biomechanics for both adults and pediatrics. Dr. DeCaro is President and fellow of the American College of Foot & Ankle Pediatrics (ACFAP). He

is board certified by the American Board of Multiple Specialties in Podiatry, is in private practice in West Hatfield, MA, and is a member of the surgical and medical staff at Franklin Medical Center as well as Holyoke Medical Center. email him at louisdecaro@decaropodiatry.com for further information and/or questions.

86

SEPTEMBER 2022 | **PODIATRY MANAGEMENT**

podiatrym.com